

New Zealand Aquatic  
Environment and Biodiversity  
Report No. 34  
2009  
ISSN 1176-9440

Necropsy of marine mammals  
captured in New Zealand fisheries  
in the 2007–08 fishing year

Wendi D. Roe

**Necropsy of marine mammals  
captured in New Zealand fisheries  
in the 2007–08 fishing year**

Wendi D. Roe

New Zealand Wildlife Health Centre  
Institute of Veterinary, Animal and Biomedical Sciences  
Massey University  
Private Bag 11222  
Palmerston North 4442

**Published by Ministry of Fisheries**  
**Wellington**  
**2009**

**ISSN 1176-9440**

©  
**Ministry of Fisheries**  
**2009**

Citation:  
Roe, W.D. (2009).  
Necropsy of marine mammals captured in New Zealand fisheries in the  
2007–08 fishing year.  
*New Zealand Aquatic Environment and Biodiversity Report No. 34.* 35 p.

This series continues the  
*Marine Biodiversity Biosecurity Report* series  
which ceased with No. 7 in February 2005.

## EXECUTIVE SUMMARY

**Roe, W.D. (2009). Necropsy of marine mammals captured in New Zealand fisheries in the 2007–08 fishing year.**

*New Zealand Aquatic Environment and Biodiversity Report No.34. 35 p.*

Confirmation of species and sex, as well as description of morphometric characteristics, age class, stomach contents, reproductive status, and entrapment-related pathology are described for five New Zealand sea lions (*Phocarcos hookeri*) and one fur seal (*Arctocephalus forsteri*) returned from the SQU 6T fishery in the 2007-08 fishing season. All were caught between 28 February and 26 April 2008. Two adult male New Zealand sea lions were also returned from the Southern blue whiting fishery, one caught in September 2007 (SB08-06Ph) and one in September 2008 (SB08-10Ph).

Three of the SQU 6T sea lions were females and two were males. Of the females, one was approximately one year old, and two were sexually mature with *corpora lutea* in their ovaries (indicating an early stage pregnancy). Neither of the adult females was lactating. Both males and one female had Department of Conservation flipper tags and hence could be accurately aged: the female was born in 2004, the first male was born in 2007 and the second in 2006. Histology of the testes and the summed testicular masses of the two males were consistent with sexual immaturity.

All animals were retrieved from trawl nets and had lesions consistent with drowning/asphyxia, including pulmonary congestion and oedema, and foam in the airways. In addition, all had evidence of various degrees of blunt trauma. For the five sea lions returned from the SQU 6T fishery, trauma was assessed as mild in three, moderate in one, and severe in one. Both of the sea lions from the southern blue whiting fishery were assessed as having severe trauma based on apparent bruises (contusions) in the brain. Sea lion exclusion devices (SLEDs) are used in the SQU 6T fishery, but not in the southern blue whiting fishery.

## **1. INTRODUCTION**

This report details findings from the 2007-08 fishing season, during which seven New Zealand sea lions (*Phocarctos hookeri*) and one New Zealand fur seal (*Arctocephalus forsteri*) were returned for examination. The objectives of this study were as follows.

### **Overall objective**

1. To examine marine mammals captured in New Zealand fishing operations during the 2007-08 fishing year to determine species and life-history characteristics.

### **Specific objectives**

1. To determine, through examination of returned marine mammal carcasses, the species, sex, reproductive status, and age-class of marine mammals returned from New Zealand fisheries.
2. To detail any injuries, and, where possible, the cause of mortality of marine mammals returned from New Zealand fisheries, and examine relationships between injuries and body condition, breeding status, and other associated demographics.

## **2. METHODS**

### **2.1 General necropsy protocol**

Carcasses were delivered to Massey University, frozen and wrapped in clear plastic bags and woven nylon phages (sacks). Conservation of Services Programme (CSP) data sheets are completed by on-board observers in the SQU 6T fishery, and are usually returned with the bodies. On receipt, the carcasses were frozen in a  $-20^{\circ}\text{C}$  freezer until necropsy could be undertaken. For three animals (SB08-02Ph, SB08-05Ph, SB08-06Ph) the heads were removed with a hand saw while the bodies were still frozen, and the head then sectioned in half with a band saw, exposing the brain. The two halves were then placed into a large container of 10% buffered formalin so that the brain thawed out in fixative. This was undertaken to determine if thawing in fixative would improve the preservation of the brain tissue for microscopic analysis. Once adequate fixation had taken place, these heads were flensed and the brains removed as described for the other animals (see below). The rest of the body was placed in a  $-20^{\circ}\text{C}$  freezer pending necropsy. Bodies were removed from the freezer and thawed at room temperature for 3 -4 days before necropsy.

The species and sex were determined based on external morphology and expertise of the examiner. Each animal was assigned three codes: the CSP code as submitted, a Massey University pathology code (five digit), and unique code to identify the animal's provenance and species as follows:

SB05-01Ph:

SB—Seal bycatch, 05 — year, 01 — animal number, and Ph — abbreviation of species scientific name (*Phocarcos hookeri*).

Pathological examination and sampling was conducted according to a standard protocol (Duignan et al. 2003a; Roe 2007a, 2007b). The procedure includes recording the body weight (kg), external measurements (m), and examination of the carcass for external lesions indicative of trauma, for example hair loss, lacerations, scars, fractures. In 2005-06, at the request of the Aquatic Environment Working Group, several additional measurements were added to those previously made at necropsy. These were depth, girth, and width measurements of the head and shoulders. These measurements were thought likely to be associated with whether or not an animal was able to pass through the SLED bars. Significant lesions were documented on a body map diagram. The body was opened along the ventral midline and the blubber depth (mm) was recorded over the mid-sternum. A small skin sample was collected from the pectoral or pelvic flipper and stored in 70% ethanol for genetic analysis. The skin and hair were removed, and any bruising was noted on a body map diagram, with an assessment of the amount of the body involved, location, and depth of the bruising. Blubber samples were taken from the dorsal aspect of the left pelvis for fatty acid analysis (used in diet determination), and stored at  $-80^{\circ}\text{C}$  for further research. In females the mammary gland was sliced at 5 - 10mm intervals along its length to evaluate the presence of milk, and samples were collected into buffered formalin for microscopic analysis.

The body cavity was then opened. Abdominal fluid was removed and measured. Tissue samples were collected from lung, liver, spleen and kidneys and frozen at  $-20^{\circ}\text{C}$ . These tissues can be used for virology, bacteriology, and toxicology at a later date. The tongue, trachea, and oesophagus were dissected out and removed along with the lungs. The trachea and lower airways were opened and examined, and multiple incisions were made into the lung tissue. The heart was opened and all chambers and walls examined. The stomach was removed, tied off, and either examined immediately or frozen at  $-20^{\circ}\text{C}$  until the contents could be examined at a later date. The liver was assessed for tears or ruptures, and for evidence of disease. The hepatic sinus and gall bladder were examined, as were the spleen, pancreas, and adrenals. Samples of each of these tissues were saved in buffered formalin. In females, the reproductive tract was dissected out and the uterine horns were opened and examined for signs of pregnancy. A sample of uterus was collected into buffered formalin. The length, width, and depth of the ovaries were measured (mm) using vernier calipers, and the ovaries weighed (g). The ovaries were examined grossly for the presence of *corpora lutea* (CL; evidence of a current pregnancy) and *corpora albicantia* (CA; evidence of a previous pregnancy). Both ovaries were saved in buffered formalin. In males, the testes were removed, weighed, and measured and a sample was saved in buffered formalin. Kidney capsules were removed and the kidney was examined for evidence of trauma or disease.

The head was carefully skinned and examined for bruising and fractures. The mandible was dissected out, tagged, and frozen at  $-20^{\circ}\text{C}$  for future ageing by cementum or dentine analysis of teeth. The brain was then removed by sectioning the head with a band-saw and carefully breaking down attachments between the skull and brain tissue. The surface of the brain was examined grossly and the brain was then fixed in buffered formalin for at least two weeks. Once adequately fixed, the brain was removed and again examined grossly for detection of bruising (contusions).

### **2.3 Pathology**

During the necropsy particular note was taken of any lesions that might be attributable to trauma. The aim of this was to assist in monitoring the effectiveness of sea lion exclusion devices (SLEDs) deployed in vessels in order to exclude sea lions and other large non-target species from nets. These lesions can

include fractures, bruising, and damage to internal organs.

Traumatic lesions were assessed in three categories: body wall subcutaneous/skeletal, cranial, and abdominal cavity. The severity of trauma in each category was then assessed as follows:

- subcutaneous/skeletal trauma was classified as mild, moderate, or severe based on the amount of tissue involved, the depth of bruising, and the presence or absence of ante-mortem skeletal fractures

- cranial trauma was assessed as mild, moderate, or severe based on extent of tissue involved and depth of bruising. If haemorrhage was present within the skull or in the brain tissue, trauma was classified as severe.

- body cavity haemorrhage was classified as moderate or severe based on the volume of blood present in these cavities and the specific organs involved (e.g. liver, spleen, large vessels).

These results are included in Appendix 1. A subjective assessment of the overall severity of trauma (mild, moderate, or severe) was then given based on the assumed combined effect of trauma in each category.

## **2.4 Stomach content analysis**

The stomachs were weighed (kg), opened using scissors and all material was washed into a 1 mm sieve. The stomach was then re-weighed to determine the weight of the stomach contents. Large, relatively undigested material was then removed. Smaller, more digested material was gradually sorted using a black-bottomed tray. Otoliths were clearly visible against this background, and as they are denser than most of the other material, they sink to the bottom of the tray. Squid beaks, eye lenses, fish bones, and other relevant food material were also collected. Lesions in the gastric mucosa were described and quantified. Otoliths, bones, and squid beaks were stored in 70% alcohol for more detailed analysis of diet.

## **2.5 Histological (microscopic) analysis**

Tissues were fixed in 10% buffered formalin before preparation for microscopic analysis. Briefly, this involved trimming tissues into 2 mm blocks, then embedding them in paraffin for routine histochemical processing. Processed tissues were sectioned at 5 µm intervals using a microtome, mounted on glass slides, and stained with haematoxylin and eosin. Slides were examined microscopically at x40 to x100 magnification.

Testes were examined microscopically to assess the maturity of the seminiferous tubule epithelium and evaluate the presence of spermatozoa. The microscopic characteristics of the testicular and epididymal tissue, in conjunction with the combined weight of the testes (summed testicular mass), of an individual male enable its classification as sexually mature (with active or inactive spermatozoa production as appropriate), immature, or pubertal.

Ovaries were examined to confirm the presence of *corpora lutea* or *albicantia* as assessed grossly. The uterine horns were also examined to assess the maturity of the reproductive tract, and mammary tissue was assessed for the presence of milk and for evidence of any inflammatory response (mastitis) or disease.

Sections of lung were examined to determine the presence or absence of pulmonary congestion and oedema (excessive blood in vessels and excessive fluid in the airways) as these are indicators of drowning.

Sections of trachea, oesophagus, spleen, adrenal, gland, liver, heart, diaphragm, and kidney, as well as the whole brain, were saved for histological analysis as indicated.

### **3. RESULTS**

#### **3.1 Catch data and observers' reports**

This year CSP data sheets were included with all but one SQU 6T sea lion (SB08-03Ph). Photocopies of Observer Non-fish Bycatch Forms for the SQU 6T animals were made available for review following completion of all necropsies. The fur seal (SB08-04Af) was from an unobserved vessel, and arrived with a CSP data sheet, but no Observer Non-fish Bycatch Form was available. In the SQU 6T fishery, one vessel returned two sea lions, and three other vessels returned one each. Two sea lions were reported to have been found in the pounds following opening of the codend of the net only (i.e., are assumed to have gone through the SLED).

Forms were not available for animals from the southern blue whiting fishery.

Capture data are summarised in Table 1. The following comments were recorded on Observer Non-fish Bycatch Forms for animals returned from the SQU 6T fishery:

SB08-01Ph: First seen in pounds; net only opened on codend side of SLED. Sample taken from flipper.

SB08-02Ph: First seen in pounds; net only opened on codend side of SLED.

SB08-03Ph: First seen at the grid, in the SLED lengthener.

SB08-05Ph: Caught in SLED.

SB08-09Ph: No comments recorded

#### **3.2 Morphometrics**

An extensive set of measurements was taken from each individual (Table 2). All animals were assessed as being in good body condition based on blubber depths and internal fat stores. (See also the General comments for each animal in Appendix 1.)

The number of sea lions submitted from SQU 6T this season (5) was low, continuing a trend observed in recent years. Eight sea lions were returned in the 2006-07 season, 11 sea lions in 2005-06, 13 in 2004-05, 23 in 2003-04, 14 in 2002-03, 21 in 2001-02, 40 in 2000-01, 28 in 1999-2000, and 27 in 1997-98 (Duignan et al. 2003a, 2003b, 2003c; Roe, 2007a, 2007b). Females made up 60% of the bycaught sea lions from SQU 6T this year. The proportion of females has varied greatly over the years, ranging from 30% in 1997-98, to 91% in 2005-06. Of 190 recorded bycaught sea lion necropsies performed since 1997-98, 116 (61%) have been females.

Two sea lions were assessed as having passed through the bars of the SLED. Each animal was from a different fishing vessel. Both these animals were young, and physically smaller than the others in weight and body length. Figure 1 shows head and shoulder measurements for the animals from SQU 6T.



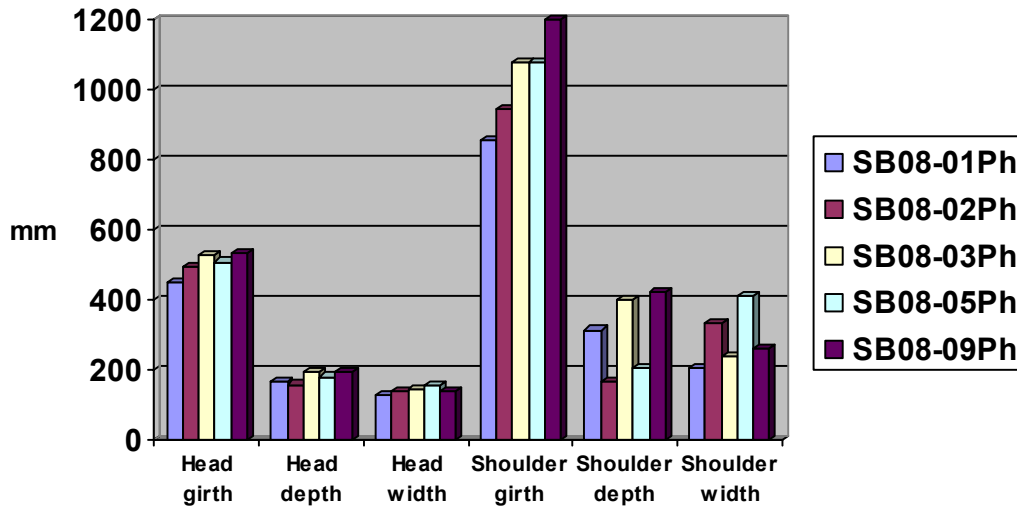


Figure 1: Comparison of morphometric measurements for sea lions returned in 2007–08. SB08-01Ph and SB08-02Ph were both found in the codend of the net.

### 3.3 Stomach contents

Analysis of the stomach contents of SQU 6T sea lions revealed a mixture of squid and fish at diverse degrees of digestion, except for one male that had only fish remains in its stomach. Most of the free otoliths found belonged to the rattail family and to the opalfish family. Southern blue whiting, either fresh or digested, made up the bulk of the stomach contents from the two males caught by the southern blue whiting fishery; there was no evidence of arrow squid remains in the stomach contents of these two animals. Details are given in Table 3.

### 3.4 Age determination

Accurate determination of age was possible for three sea lions that had Department of Conservation flipper tags. One of these animals was tagged as a pup in 2007 (SB08-02Ph; 1 year old male), one in 2006 (SB08-05Ph; 2 year old male) and one in 2004 (SB08-03Ph; 4 year old female) (L. Chilvers, Department of Conservation, pers. comm.). The mandibular teeth have been collected from all animals to enable ageing by microscopic analysis of cementum/dentine layers at a later date.

### 3.5 Reproductive status

Details are provided in Tables 4 and 5.

#### 3.5.1 Females

Two of the three female sea lions returned this year showed evidence of a current pregnancy in the form of ovarian *corpora lutea*. They were not lactating, therefore had not had a pup this season. As with previous studies (Duignan et al. 2003b, Roe 2007a, 2007b) no detectable foetuses were present, consistent with a recent pregnancy and delayed implantation/embryonic diapause. The third female was small, with inactive ovaries and mammary tissue. Based on body weight and length, this female was likely to have been born in 2007.

### **3.5.2 Males**

Both SQU 6T males were sexually immature, based on histological examination of the testes and on summed testicular mass (STM) values. Previous analyses (P. Duignan, currently Department of Agriculture and Food, Ireland, unpublished data) have established summed testicular mass ranges of 55-105 g for mature males and 23–32 g for immature males. Both males from the southern blue whiting fishery were mature.

### **3.5.3 Fur seal**

The fur seal was a sexually mature male.

## **3.6 PATHOLOGY**

This report describes gross lesions associated with capture and with freezing and storage of bodies. Chronic lesions such as old wounds are not described. Details of gross lesions are given in Table 6, and diagrams for each animal are given in Appendix 2.

### **3.6.1 Cause of death**

Each animal had lung lesions consistent with death due to drowning/asphyxia, comprising severe bilateral pulmonary congestion and oedema, with the presence of fluid and foam in the trachea and bronchi.

### **3.6.2 Body wall trauma (bruising and/or skeletal fractures)**

Four SQU 6T sea lions had bruising of the body walls, varying in severity from localised bruising of the blubber affecting 5% or less of the body surface (SB08-03Ph, SB08-09Ph and SB08-05Ph), to mid-depth bruising involving blubber and superficial muscle and affecting approximately 20% of the body surface (SB08-02Ph). The fifth sea lion, a young female that had gone through the bars of the SLED, had no bruising of the body wall (SB08-01Ph). In three sea lions the bruising included a strip of blubber along the ventral chest/sternum. The fur seal (SB08-04Af) had small superficial bruises of the sternum, left shoulder, and right ear.

One of the southern blue whiting animals had bruising of the right shoulder, affecting less than 5% of the total trunk. The large male (SB08-10Ph) had a strip of bruising affecting the deeper muscle layers of the sternum, and similar bruising of the right shoulder. Neither of these animals would have encountered a SLED.

No animals had bone fractures.

### **3.6.3 Head trauma**

Findings are summarised in Table 7.

Two of the SQU 6T sea lions (SB08-01Ph and SB08-09Ph) had bruising to the soft tissues of the chin, snout, ear or throat. In SB08-01Ph the bruising was comparatively shallow and affected a smaller area than in SB08-09Ph. SB08-01Ph was found in the codend of the net while the location of SB08-09Ph was not recorded.

Neither of the animals from the southern blue whiting fishery had bruising to the head or face.

Focal brain contusions were not present in any of the SQU 6T animals. All of the animals in which the brain was removed after full thawing had pronounced dark red staining of one side of the brain (unilateral discolouration). This staining was not present in any that had the brain fixed while still frozen. The brain of SB08-01Ph was removed after full thawing, and had extensive dark red mottling of the base of the brain, extending onto the lateral surfaces. The discolouration was much more pronounced on the left side. This animal was found in the codend of the net. No other SQU 6T sea lions had soft tissue bruising to the head or contusions of the brain, including the other sea lion that was found in the codend.

Both southern blue whiting sea lions had dark red discolouration of one or both occipital brain lobes (the lobes at the back of the cortex). Neither of these sea lions had bruising of the head or face.

### **3.6.4 Body cavity lesions**

All animals had blood-stained fluid in the abdominal cavity. The volume varied from 100 to 380 ml. None of the bodies had any evidence of blunt trauma to abdominal organs, and none had evidence of rupture of any major blood vessels. In each case the hepatic sinus was intact.

Each animal had apparent haemorrhage into the renal capsule, with the total volume of blood involved in each case estimated to be less than 2–5 ml. In each case the capsules were removed, showing the kidneys themselves to be grossly normal. All animals also had dark bruised suspensory ligaments of the urogenital tract.

### **3.6.5 Post mortem trauma**

Two sea lions (SB08-01Ph and SB08-09Ph) had recently sustained flipper wounds. Gross and histological examination indicated that these wounds were caused after death. The observer report for SB08-01Ph noted that tissue had been removed from a flipper for genetic analysis.

## 4. DISCUSSION

### 4.1 General comments and life history parameters

Although the numbers of animals in this data set are too small to allow statistically valid comparisons to be made, review of Figure 1 suggests that shoulder girth might be the only variable that is appreciably lower in the animals that passed through the grid. In my experience, measurement of shoulder depth and width is difficult and unreliable, as the shoulders are relatively mobile structures and measurements tend to change with body position. In contrast, girth measurements are relatively repeatable, and the head, as a single rigid structure, is also more easily and accurately measured.

Stomach content analysis from this year is consistent with previous findings. Characterisation of the diet of New Zealand sea lions is part of an ongoing project at Massey University, involving analysis of stomach contents and fatty acid signatures in blubber. Detailed analysis of stomach contents has revealed some bias inherent in the use of total stomach contents (i.e., both fresh prey items and digested parts) in determining the importance of various prey species. Using only the fresh fraction will result in an overestimate of the relative importance of arrow squid due to skewing of the sample population: animals caught in squid nets are likely to have recently ingested squid. The digested fraction of stomach contents provides a better estimate of the “background diet” of the species, reflecting prey that has been ingested in the past few days rather than in the past few hours (Meynier et al. in press). Accumulation of digested parts of prey over more than a few days is unlikely, particularly in females, as most females regurgitate some hard parts such as cephalopod beaks when they return to land (L. Chilvers, New Zealand Department of Conservation, unpublished data).

Stomach contents of 121 bycaught sea lions captured between February and May from 2000 to 2006 consisted of 33% arrow squid by prey number (N) (equivalent to 18% by prey mass (M)), 28% N of octopus (28%M), and 39% N of fish (46%M; mainly rattails, red cod, opalfish, and hoki) (Meynier et al. in press). The important contribution of arrow squid in the diet of bycaught sea lions in autumn is also supported by fatty acid analysis performed on the same animals, for which arrow squid had a similar contribution to rattails (28%M) (Meynier 2009). Although arrow squid is a main prey in the diet of bycaught New Zealand sea lions, its contribution is still lower than that of the combined fish species.

Female New Zealand sea lions apparently become sexually mature at 3 years old and can produce their first pup at 4 years (Cawthorn et al. 1985). Many females do not enter the breeding population for several more years, with first reproduction occurring in animals up to 9 years old (I. Wilkinson, New Zealand Department of Conservation, pers. comm.). In this study, neither of the two sexually mature females were lactating (i.e. had produced offspring this season). Both had *corpora lutea* in their ovaries, indicating a current pregnancy. One of these females was known to be four years of age, hence this is likely to have been her first pregnancy. Neither of the mature females had grossly or microscopically detectable embryos, which is consistent with the phenomenon of embryonic diapause, as occurs in most pinniped species (Gales 1995).

Male New Zealand sea lions become sexually mature at 5 years old but do not tend to hold territories or breed for a further 3 to 5 years (Cawthorn et al. 1985). Two of the male sea lions examined this year had immature testes, with poorly developed seminal vesicles and no histological evidence of spermatogenesis. Both males from the southern blue whiting fishery were sexually mature as assessed by summed testicular mass.

## 4.2 Pathology

Non-fish bycatch forms were made available for this first time last year. All post mortems were carried out before receipt of bycatch forms, removing the possibility of accidental introduction of bias into the descriptions of trauma. Access to this information after the completion of the post mortem reports however allowed clarification of the origin of some of the lesions found, including one post-mortem skull fracture caused by dropping an animal into the hold in 2007. Similarly, the reports this year clarified the cause of a large recent flipper wound in one sea lion (SB08-01Ph).

Last year, several bycatch forms included information about the state of rigor of the animal and the presence or absence of foam at the mouth. This information could enable an estimate to be made of the approximate time of drowning of an animal (i.e., early or late in the tow), which could in turn be useful both for possible mitigation of bycatch and in interpretation of the cause of bruising detected at necropsy. For example, an animal that is not in rigor mortis and has foam at the mouth is likely to have been captured shortly before hauling, and may sustain significant amounts of trauma while the nets are being hauled in. Unfortunately, none of this year's bycatch forms noted these details. It would be useful if this information could be included as standard in subsequent observer reports.

All the pinnipeds examined were healthy and in good body condition. The cause of death of each animal was attributed to drowning/asphyxia, based on the characteristic signs of airway foam and pulmonary congestion and oedema in all bodies examined, in conjunction with an absence of any other potential cause of death. These characteristics are based on criteria established for cetaceans (Kuiken 1994, Kuiken et al. 1994). In addition to lesions associated with drowning, all animals had some evidence of bruising to the subcutaneous tissues and/or muscle.

The overall severity of body wall trauma in bycaught animals this year was low, with one sea lion having no body wall bruising and the remainder assessed as having only mild bruising. The sea lion with no body wall bruising (SB08-01Ph) was reported as being found in the pounds with only the codend side of the net having been open, indicating that it must have passed through the bars of the SLED. The absence of bruising in this animal could be explained either by an error in recording the body's location, or because the animal was able to squeeze carefully through the bars of the grid without sustaining any trauma. This was the smallest of the animals that were captured.

Many animals have a pattern of bruising that involves the sternum and the shoulders. This pattern also seems to occur in animals recovered from vessels that do not have SLEDs (unpublished data from necropsy record sheets), including the two sea lions from the southern blue whiting fishery this year, suggesting that it is not related to SLED use. To complicate interpretation further, it is not possible to accurately age bruises, so the most that could confidently be said about the timing of this damage is that the bruises could have occurred at any time from about two days capture up until the actual time of death.

Location in the net when landed did not appear to be directly related to the amount of body wall bruising, with animals found in the codend having similar degrees and patterns of bruising to those found elsewhere in the net system. However, this is a very small sample set, and retrospective analysis of previous necropsy data, in conjunction with observer data, would be required to make more specific comments about the relationship between net position and trauma. Similar analyses may also clarify whether or not SLED use itself is related to any particular pattern or level of severity of trauma.

Removal and examination of the brain has now been a standard part of the necropsy protocol for two years. Last year, two animals (SB07-02Ph and SB07-04Ph) were found to have contusions to the occipital lobe of the brain (Roe 2007a), and it was speculated that they may have been caused by interaction with

the grid bars of the SLED. Similar lesions were not seen this year in animals from SQU 6T; however both males returned from the southern blue whiting fishery had apparent contusions of the occipital lobes. As vessels in this fishery do not deploy SLEDs, it is not possible for these lesions to be associated with damage from grid bars. In addition, neither of these two sea lions had any soft tissue bruising of the head or face, which would be unlikely if these were true contusions caused by trauma to the head. The fact that the lesions have consistently involved the occipital lobe and the absence of associated soft tissue bruising introduces the possibility that this is some form of artefact associated with freezing. Freezing artefacts are discussed in more detail in the next section.

### **4.3 Interpreting lesions in frozen animals**

A major problem in conducting necropsies on previously frozen animals is in deciding whether or not lesions reflect a true pathological process, or are a consequence of post mortem changes or handling and storage of the body. Experienced pathologists who have spent time working with frozen bodies will confirm that freezing and thawing causes lesions that can easily be misinterpreted as bruising or haemorrhage. These changes occur because ice crystals that form during freezing will expand upon thawing and cause cells to rupture. When red blood cells rupture, haemoglobin leaks out, staining surrounding tissues dark red. Red-stained fluid will accumulate in spaces such as body cavities, and reddened soft tissues will appear similar to bruises. True bruises, present before freezing, may appear larger after thawing due to staining of tissue at the margins of the bruise. The exact pattern of these artefactual lesions may depend on body and tissue shape, the amount of blood present, and possibly the position of the body during freezing and thawing. Ideally, to avoid this confounding factor pinniped necropsies would need to be performed on board vessels when the bodies are first recovered. Alternatively, comparative studies on frozen and non-frozen animals could be used to clearly establish which lesions are due to freeze-thaw artefact.

As in previous years, all animals examined this year had dark red watery fluid in the abdominal cavity. In the past this fluid was interpreted as an indication of severe abdominal trauma, and considered to impart a poor prognosis for survival. In the early reports volumes of fluid were estimated rather than measured, and were frequently reported to be one litre or more. If this fluid truly represented haemorrhage, loss of this amount of blood would have a significant impact on the animal. Quantification of the fluid has been undertaken for the past two years. This year, the volume ranged from 100 / 380 ml, similar to findings from last year, demonstrating that actual volumes of fluid present are markedly less than previously thought. In addition, preliminary results from a trial comparing chilled and frozen fur seal bodies show that volumes of fluid within this range can be produced by freezing (author's unpublished data). This conclusion is supported by the fact that none of the sea lions examined had damage to any body organs or vessels which could have caused haemorrhage into the abdomen. For this reason, the presence of abdominal fluid has not been considered in interpretations of survival prognosis.

Similarly, bruising of the kidneys and suspensory ligaments of the reproductive tract has frequently been reported in necropsies conducted in this and previous contracts (Duignan et al. 2003a, 2003b, 2003c, Roe 2007a, 2007b). Initially this lesion was considered to represent severe abdominal trauma, although the exact pathogenesis was uncertain. It now seems likely that this damage does not directly affect the kidneys themselves, but instead is confined to the capsule of the kidney. Preliminary results from a study of frozen and non-frozen bycaught fur seals indicate that 'bruising' of the kidney capsule and reproductive tract ligaments may also be an artefact of freezing (author's unpublished data). While this study is currently in its early stages and sample numbers are currently low (three fur seals examined chilled and three examined after freezing and thawing), these preliminary findings, when taken in conjunction with a knowledge of typical artefacts of freezing and the absence of any body wall bruising or skeletal damage near the 'bruised' internal organs, indicate that these lesions are not likely to be clinically significant.

I also have some concerns about interpreting brain lesions in frozen animals. This year, the heads of three sea lions were removed and bisected before thawing of the body, to allow the brains to be thawed in buffered formalin in an effort to improve cellular preservation of the brain tissue. (These animals are classified as “frozen” in the head removal column of Table 7.) The brains of the remaining animals were removed once the body had thawed (classified as “thawed” in Table 7). In each of these latter brains there was marked dark red discolouration of one side of the brain (unilateral discolouration). This change was not present in the brains from heads that were removed while frozen. As long as both sides of the brain are examined closely, this staining-type artefact is unlikely to be misinterpreted as a contusion. Although it is possible that the staining could obscure an underlying contusion, in one southern blue whiting male an occipital lobe lesion could still be seen through the staining.

One sea lion from the SQU 6T fishery (SB08-01Ph) had extensive mottled dark red discolouration of the base and one side of the brain. This sea lion had been found on the codend side of the SLED, so this damage could theoretically have been caused by the bars of the grid. This is a very unusual pattern of bruising, however, and I have not previously seen anything similar in non-frozen animals, including a pinniped (not a bycaught animal) that had been killed by several blows to the head. Once again, this raises the possibility that this lesion is partly or solely an artefact of freezing. In spite of this the animal has been classified as having had severe trauma because of the uncertainty inherent in interpreting the brain lesions combined with the presence of bruising to the face and head. A second animal that was found at the codend of the SLED (SB08-02Ph) did not have brain contusions or soft tissue bruising of the head.

Although the results from 2007-08 necropsies suggest the presence of artefacts, the relatively small sample sizes involved means that additional work is required to confirm these observations.

#### **4.4 Assessing survivability**

For SLEDs to be fully effective, animals that escape from a net after encountering a SLED should not sustain trauma that would be significant enough to impair their survival. In practice, assessing the chance of survival of a pinniped that has successfully exited a net is problematic; most of these animals, by definition, will not appear in the net at hauling. The animals that are recovered from the net are presumably there because they were, for some undetermined reason, unable to escape. This could be due to animal factors (for example young inexperienced divers that are unable to negotiate the SLED exit hole; animals entering the net at the end of their dive duration when they have insufficient oxygen to escape; animals that are severely injured by their encounter with the SLED) or to gear factors (failure of the proper functioning of the SLED). In the absence of a viable method of observing or tagging sea lions that pass through a SLED and then monitoring their survival over subsequent hours to days, however, these bycaught animals are arguably our best chance of assessing the degree of trauma caused by transit through the SLED.

To this end, this report has attempted to objectively quantify the severity of trauma in separate body systems (head, body wall/skeletal and body cavities) and to then assign an overall category of trauma severity based on the assumed combined effect of all traumatic lesions noted. The overall severity category is inherently subjective, but is based on my experience in veterinary clinical practice (10 years) and as a pathologist (9 years). Using these descriptions and assessments, experienced veterinarians would be able to subjectively determine a likely prognosis for each animal, had it managed to escape the net. In very general terms, animals having a mild degree of trauma would have a good to excellent chance of survival, those having moderate trauma would be likely to have a slightly decreased survival prognosis, while those with severe trauma are likely to have a markedly decreased chance of survival. I do not believe that it is currently possible to place an exact value on the magnitude of this decrease.

In my opinion, the body wall bruising seen in bycaught animals this year would not have any significant effect on the survival of the animals, and no animals had clear indications of significant damage to internal organs or body cavities. In contrast, trauma to the head is much more likely to have a negative effect on the chance of survival of an individual animal. Bruising to the soft tissues of the head or to the brain itself are indicators of head impact. Brain contusions represent damage to the superficial tissues and blood vessels of the brain. Unfortunately, there is no absolute correlation between the presence or severity of contusions and prognosis. For example, in human medicine it is widely recognised that patients can have severe brain contusions with no impairment of brain function, and conversely, in some fatal cases of head trauma there are no brain contusions (Adams et al. 1982, Blumbergs et al. 2008). In most of these fatal cases, microscopic examination of the brain using special stains will reveal the underlying damage (Adams et al. 1982), but this requires the patient to have survived for at least several hours post-trauma. Since bycaught sea lions are likely to drown within this time frame, this technique could not be used in these animals. Protein biomarker techniques have also been used to assess prognosis in people (Wang et al. 2005, Hortobagyi et al. 2007), but are not yet validated in pinnipeds.

Although these facts limit our ability to assess head trauma *severity*, the fact remains that the presence of bruising to the head or brain of bycaught animals would indicate that they have sustained some type of head impact, and that there is therefore the potential that their state of consciousness could have been impaired. Accordingly, I have assessed facial bruising as indicating moderate trauma, while bruising of the brain itself (brain contusion) is assessed as indicating severe trauma. Animals with the brain contusions are likely to have a significantly decreased chance of survival.

In human medicine, biomechanical modelling can be used to predict outcomes of head trauma of a specific magnitude and direction (Ommaya et al. 2002). This method may be worth investigating as a means of predicting the likely outcome for a sea lion that contacts the bars of a SLED.

#### **4.5 Conclusions**

The data presented here indicate that all pinnipeds caught during the 2007-08 season died as a result of drowning, were in good body condition, and did not have any concurrent diseases. Two animals from SQU6T had passed through the bars of the SLED; both of these animals were young and therefore of small body size. All sea lions had some degree of blunt trauma. No animals were assessed as having sustained severe enough body wall trauma or body cavity trauma to have impaired their chances of survival had they been able to escape the net. Preliminary results from a trial being conducted on bycaught fur seals suggest that the abdominal fluid and kidney lesions previously believed to be caused by severe trauma are actually an artefact of freezing.

The most important lesions in terms of survival prognosis are likely to be those of head trauma. Two sea lions from SQU 6T had evidence of head trauma that may have affected their survival chances.

Focal contusions of the occipital brain lobes were seen in sea lions returned from vessels without SLEDs (the two animals from the southern blue whiting fishery). Similar lesions were present in sea lions from the SQU 6T fishery last year and were interpreted as being due to trauma. Their presence in animals from vessels without SLEDs raises the possibility that these lesions are either not associated with SLED interaction, or are artefactual. Recommendations for further work include expanded investigations of freeze-thaw artefacts (including brain lesions), evaluation of protein-based techniques such as biomarker assays which may be able to assess the severity of head trauma, consideration of biomechanical modelling as a tool for assessing head impact severity, and examination of relationships between trauma types and specific circumstances of capture. Inclusion of additional information on observer reports (especially with



respect to rigor mortis status and the presence or absence of foam at the nose and mouth) would also be useful.

## 5. ACKNOWLEDGMENTS

Thanks are due to the following staff and post-graduate students at Massey University: Laureline Meynier, Kelly Buckle, Laura Donaldson, and Lynn Rogers for technical and scientific assistance and data entry; Evelyn Lupton, Elaine Booker, and Nicola Wallace for preparation of histological sections; Mike Hogan and Brodie Borrett for assistance in the post mortem room; and Sharon Hawira-Seanoa for management of the contract accounts. This work was funded by the Ministry of Fisheries.

## 6. REFERENCES

- Adams, J.H.; Graham, D.I.; Murray, L.S.; Scott, G. (1982). Diffuse axonal injury due to nonmissile head-injury in humans -an analysis of 45 cases. *Annals of Neurology* 12(6): 557–563.
- Blumbergs, P.; Reilly, P.; Vink, R. (2008). Trauma. In: Love, S.; Louis, D.N.; Ellison, D.W. (eds). *Greenfield's Neuropathology*, p 753. Hodder Arnold, London.
- Cawthorn, M.W.; Crawley, M.C.; Mattlin, R.H.; Wilson, G.J. (1985). Research on pinnipeds in New Zealand. Pinniped Research Review Sub-Committee, Wellington. (Copy available from W. Roe, IVABS, Massey University, Private Bag 11222, Palmerston North 4442.)
- Duignan, P.J.; Gibbs, N.J.; Jones, G.W. (2003a). Autopsy of pinnipeds incidentally caught in commercial fisheries, 2001/02. *DOC Science Internal Series 131*.
- Duignan, P.J.; Gibbs, N.J.; Jones, G.W. (2003b). Autopsy of pinnipeds incidentally caught in fishing operations 1997/98, 1999/2000, and 2000/01. *DOC Science Internal Series 119*.
- Duignan, P.J.; Gibbs, N.J.; Jones, G.W. (2003c). Autopsy of pinnipeds incidentally caught in fishing operations 1997/98, 1999/2000, and 2000/01. New Zealand Department of Conservation. 106 p.
- Gales, N. (1995). Hooker's sea lion recovery plan (*Phocarctos hookeri*). *Department of Conservation Threatened Species Recovery Plan 17*.
- Hortobagyi, T.; Wise, S.; Hunt, N.; Cary, N.; Djurovic, V.; Fegan-Earl, A.; Shorrocks, K.; Rouse, D.; Al-Sarraj, S. (2007). Traumatic axonal damage in the brain can be detected using beta-APP immunohistochemistry within 35 min after head injury to human adults. *Neuropathology and Applied Neurobiology* 33(2): 226–237.
- Kuiken, T. (1994). Review of the criteria for the diagnosis of bycatch in cetaceans. *European Cetacean Society Newsletter, Special Issue 26*: 38–43.

Kuiken, T.; Simpson, V.R.; Allchin, C.R.; Bennett, P.M.; Codd, G.A.; Harris, E.A.; Howes, G.J.; Kennedy, S.; Kirkwood, J.K.; Law, R.J.; Merrett, N.R.; Phillips, S. (1994). Mass mortality of common dolphins (*Delphinus-Delphis*) in south-west England due to incidental capture in fishing gear. *Veterinary Record* 134(4): 81–89.

Meynier, L.; Mackenzie, D.D.S.; Duignan, P.J.; Chilvers BL.; Morel, P.C.H. (in press) Variability in the diet of New Zealand sea lion (*Phocarctos hookeri*) at the Auckland Islands. *New Zealand. Marine Mammal Science*.

Meynier, L. (2009). Feeding ecology of the New Zealand sea lion *Phocarctos hookeri*. Unpublished PhD thesis, Massey University, Palmerston North, New Zealand, 193 p.

Ommaya, A.K.; Goldsmith, W.; Thibault, L. (2002). Biomechanics and neuropathology of adult and paediatric head injury. *British Journal of Neurosurgery* 16(3): 220–242.

Roe, W. (2007a). Necropsy of marine mammals captured in New Zealand fisheries in the 2006-07 fishing year. Unpublished report for the Ministry of Fisheries Aquatic Environment Working Group. (Copy held at Ministry of Fisheries, Wellington.)

Roe, W.D. (2007b). Necropsy of marine mammals captured in New Zealand fisheries in the 2005–06 fishing year. *New Zealand Aquatic Environment and Biodiversity Report No.11*. 24 p.

Wang, K.K.W.; Ottens, A.K.; Liu, M.C.; Lewis, S.B.; Meegan, C.; Oli, M.; Tortella, F.C.; Hayes, R.L. (2005). Proteomic identification of biomarkers of traumatic brain injury. *Expert Review of Proteomics* 2(4): 603–614.

**Table 1: Capture data.**

Code	CSP no.	Other tag	Date captured	Vessel code	Location	Age class	Known age
<b>SQU6T Female SLs</b>							
SB08-01Ph	1831	none	5/03/2008	A	50.05S 166.25E	juvenile	
SB08-03Ph	6628	4812	28/02/2008	B	50.13S 166.29E	adult	4
SB08-09Ph	1534	none	26/04/2008	E	56.13S 166.34E	adult	
<b>SQU6T Male SLs</b>							
SB08-02Ph	6629	7588	19/03/2008	B	49.39S 166.23E	juvenile	1
SB08-05Ph	6960	6254	14/03/2008	D	49.57S 166.19E	juvenile	2
<b>SQU6T Male Fur seal</b>							
SB08-04Af	531	none	28/02/2008	C	50.13S 166.13E		
<b>S BI Whiting males</b>							
SB08-06Ph	6656	none	24/09/2007	C	51.59S 171.38E	adult	
SB08-10Ph	6969	none	7/09/2008	F	53.25S 170.31E	adult	

**Key:**

CSP = Conservation Services Program; SBI = southern blue whiting

**Table 2: Morphometric data.**

Code	Weight (kg)	Std lgth (m)	Head		Shoulders		Girth @		PecBD (mm)	PelBD (mm)
			Depth (mm)	Width (mm)	Depth (mm)	Girth (mm)	axilla (mm)	Width (mm)		
<b>SQU 6T Females</b>										
SB08-01Ph	43	1.265	165	129	314	855	874	205	25	17
SB08-03Ph	79	1.580	196	143	398	1080	1060	240	22	20
SB08-09Ph	80	1.685	193	140	420	1200	1170	259	20	16
<b>SQU 6T Males</b>										
SB08-02Ph	53	1.325	158	139	165	945	860	335	25	18
SB08-05Ph	74	1.365	180	155	205	1080	1050	155	32	22
<b>SBI Whiting</b>										
SB08-06Ph	114	1.635	200	172	300	1290	1135	485	24	23
SB08-10Ph	295	2.245	323	192	630	1640	375	48	48	N/A

**Key:**

Std lgth = standard length; PecBD = pectoral blubber depth; PelBD = pelvic blubber depth; SBI = southern blue whiting

**Table 3: Stomach contents.**

Code	Mass of Content (kg)	Composition
<b>SQU 6T</b>		
<b>Females</b>		
SB08-01Ph	0.812	1 semi-digested squid, 1 sepiolid beak, otoliths (rattail, dwarf cod, opalfish), fish bones and flesh
SB08-03Ph	0.163	1 squid mantle, 1 squid beak, otoliths (rattail, opalfish), fish bones
SB08-09Ph	0.817	squid beaks, squid flesh, otoliths (hoki), fish bones
<b>SQU 6T</b>		
<b>Males</b>		
SB08-02Ph	1.209	~ 10 semi-digested fish (some are pigfish), otoliths (rattail, opalfish), fish bones and flesh
SB08-05Ph	1.098	3 semi-digested squid, squid beaks, otoliths (rattail, opalfish), fish bones
<b>SBI Whiting</b>		
SB08-06Ph	lost data	otoliths (SBI whiting), fish bones
SB08-10Ph	2.138	octopus beaks, ~ 6 semi-digested fish, otoliths (SBI whiting), fish bones and flesh, 1 stone

Key: SBI = southern blue whiting

**Table 4: Reproductive status, females.**

Code	Age class		Right horn diameter (mm)		Left horn diameter (mm)		Milk present?	
	ovary (g)	CL (mm)	CA (no.)	ovary (g)	CL (mm)	CA (no.)	CL (mm)	
<b>Female SLs</b>								
SB08-01Ph	juvenile	3.8	9	4.0	none	8	none	no
SB08-03Ph	adult	22.7	14	13.9	22.0	12	none	no
SB08-09Ph	adult	19.5	18	35.5	none	20	25.0	no

**Key:**

CA = corpus albicans

CL = corpus luteum

**Table 5: Reproductive status, males.**

Code	Age	Class	Left testis		Right testis		STM		
			with ep (g)	minus ep (g)	length x diam (mm)	with ep (g)	minus ep (g)	length x diam (mm)	length x (g)
<b>Male SLs</b>									
SB08-02Ph		juvenile	4.6	3.2	38 x 12	3.8	2.8	36 x 12	7.4
SB08-05Ph		juvenile	13.9	10.0	52 x 15	10.9	8.0	51 x 20	18.0
<b>Male Fur seal</b>									
SB08-04Af			10.5	7.1	42 x 23	9.6	6.9	45 x 20	17.4
<b>SBI Whiting</b>									
SB08-06Ph		adult	34.6	28.5	81 x 30	31.2	24.4	74 x 28	52.9
SB08-10Ph		adult	45.4	34.1	77 x 34	38.7	27.6	73 x 31	61.7

**Key:**

ep = epididymis, diam = diameter; SBI = southern blue;  
STM = summed testicular mass

**Table 6: Pathology.**

Code	CSP tag	Gross lesions	Severity of trauma
<b>Female sea lions</b>			
SB08-01Ph	1831	1,2,3,4,6	Severe
SB08-03Ph	6628	1,4,5,6	Mild
SB08-09Ph	1534	1,2,4,5,6	Moderate
<b>Male sea lions</b>			
SB08-02Ph	6629	1,4,5,6	Mild
SB08-05Ph	6960	1,4,5,6	Mild
<b>Fur seal</b>			
SB08-04Af	531	1,2,4,5,6	Moderate
<b>SBI Whiting</b>			
SB08-06Ph	6656	1,3,4,5,6	Severe
SB08-10Ph	6969	1,3,4,5,6	Severe

**Key:**

1. Pulmonary congestion and oedema
2. Trauma to soft tissues of head
3. Brain contusions
4. Haemorrhage in renal capsule
5. Bruising of body wall
6. Blood-tinged fluid in abdominal cavity



**Table 7: Head and brain examination.**

	Head removal	Focal contusions	Unilateral discolouration	Head/face bruising
<b><u>SQU 6T</u></b>				
<b>Female sea lions</b>				
SB08-01Ph	thawed	*	yes	yes
SB08-03Ph	thawed	no	yes	no
SB08-09Ph	thawed	no	yes	yes
<b>Male sea lions</b>				
SB08-02Ph	frozen	no	no	no
SB08-05Ph	frozen	no	no	no
<b>Fur seal</b>				
SB08-04Af	not done	not done	not done	no
<b><u>SBW</u></b>				
SB08-06Ph	frozen	occipital, cerebellum	no	no
SB08-10Ph	thawed	occipital	yes	no

\* extensive dark red mottling of surface, more pronounced on left

## Appendix 1

### Gross pathology notes for each animal

#### 1. SQU 6T Animals:

##### SB08-01Ph

*General:* Juvenile female estimated at one year old based on body size. Good body condition.

*Alimentary system and abdominal cavity:* Nematodes in oral cavity. Ingesta in oesophagus but not pharynx. 250 ml dark red watery abdominal fluid. Renal capsular oedema and dark red discolouration both lumbar surfaces and poles.

*Respiratory system:* Lungs very dark red and heavy (pulmonary congestion and oedema) with some inflated alveoli. Scant froth in bronchi.

*Traumatic lesions:*

Head: Minor bruising to chin and throat. Unusual bruising pattern affecting ventral and lateral brain surfaces

Body wall/skeletal: None

Abdominal cavity: [abdominal fluid + kidney lesions]

*Cause of death:* Drowning/asphyxia

*Assessment of traumatic lesions:*

Cranium: Severe

Subcutaneous/skeletal: None

Body cavities: None

Overall assessment of trauma severity: **Severe**

##### SB08-02Ph

*General:* One year old male (tagged). Good body condition.

*Alimentary system and abdominal cavity:* 380 ml dark red watery fluid in abdominal cavity. Apparent bruising of lumbar surfaces of both kidneys and tunica vaginalis both sides.

*Respiratory system:* Severe congestion and oedema both lungs. Small amount froth in airways.

*Traumatic lesions:*

Head: None

Body wall/skeletal: Superficial bruising (approx 20% trunk) affecting blubber along sternum and on right shoulder.

Abdominal cavity: [380 ml abdominal fluid; kidney lesions]

*Cause of death:* Drowning/asphyxia

*Assessment of traumatic lesions:*

Cranium: None

Subcutaneous/skeletal: Mild

Body cavities: None

Overall assessment of trauma severity: **Mild**

### **SB08-03Ph**

*General:* Four year old female (tagged). Good body condition. “Nibble” marks around eye margins and one ear (scavenged in net?).

*Alimentary system and abdominal cavity:* 100 ml dark red watery abdominal fluid. Apparent bruising of both kidneys at lumbar surfaces.

*Respiratory system:* Severe pulmonary congestion and oedema both lungs. Moderate amounts of foam in trachea.

*Traumatic lesions:*

Head: No soft tissue bruising, no brain contusions

Body wall/skeletal: Superficial bruising in strip along sternum.  
(approx 5% of trunk).

Abdominal cavity: [abdominal fluid + kidney lesions]

*Cause of death:* Drowning/asphyxia

*Assessment of traumatic lesions:*

Cranium: None

Subcutaneous/skeletal: Mild

Body cavities: None

Overall assessment of trauma severity: **Mild**

### **SB08-05Ph**

*General:* 2 year old male (tagged). Good body condition.

*Alimentary system and abdominal cavity:* Nematodes in oesophagus and pharynx. 100 ml dark red watery fluid in abdominal cavity. Apparent bruising of kidneys and tunica vaginalis.

*Respiratory system:* Severe congestion and oedema of both lungs with abundant semi-frozen foam in trachea.

*Traumatic lesions:*

Head: No soft tissue or brain bruising

Body wall/skeletal: Thin strip of bruised blubber along  
sternum (<5% of trunk)

Abdominal cavity: [abdominal fluid + kidney lesions]

*Cause of death:* Drowning/asphyxia

*Assessment of traumatic lesions:*

Cranium: None

Subcutaneous/skeletal: Mild

Body cavities: None

Overall assessment of trauma severity: **Mild**

## **SB08-09Ph**

*General:* Adult female, assessed as pregnant. Several old wounds, well healed. Good body condition.

*Alimentary system and abdominal cavity:* 180 ml dark red watery abdominal fluid. Kidneys appear bruised. A few nematodes in oesophagus but no ingesta.

*Respiratory system:* Severe bilateral lung congestion and oedema with abundant foam in airways.

*Traumatic lesions:*

Head: Deep bruising of chin and snout; bruising around left ear. No brain contusions.

Body wall/skeletal: Superficial bruising (blubber only) of focal area behind left shoulder.

Abdominal cavity: [abdominal fluid + kidney lesions]

*Cause of death:* Drowning/asphyxia

*Assessment of traumatic lesions:*

Cranium: Moderate

Subcutaneous/skeletal: Mild

Body cavities: None

Overall assessment of trauma severity: **Moderate**

## **2. Southern blue whiting animals:**

### **SB08-06Ph**

*General:* Adult male. Several wounds, all assessed as being inflicted post mortem. Good body condition.

*Alimentary system and abdominal cavity:* 350 ml dark red watery abdominal fluid. Kidneys and suspensory ligaments of testes appear bruised.

*Respiratory system:* Severe bilateral congestion with fluid and foam in airways.

*Traumatic lesions:*

Head: No head or face bruising. Left occipital lobe appears contused.

Body wall/skeletal: Bruising of blubber and muscle over right shoulder. <5% trunk affected.

Abdominal cavity: [abdominal fluid + kidney lesions]

*Cause of death:* Drowning/asphyxia

*Assessment of traumatic lesions:*

Cranium: Severe (based on occipital lobe contusion)

Subcutaneous/skeletal: Mild

Body cavities: None

Overall assessment of trauma severity: **Severe**

## **SB08-10Ph**

*General:* Large adult male. Southern blue whiting fishery. Good body condition.

*Alimentary system and abdominal cavity:* Abundant, still partially frozen dark red fluid in abdominal cavity. Unable to quantify due to size of animal. Scrotal sac distended with similar fluid; suspensory ligaments distended and discoloured also.

*Respiratory system:* Frozen fluid in trachea. Lungs heavy and dark red, especially on left.

*Traumatic lesions:*

Head: No face or head bruising. Left side of brain discoloured dark red. Apparent contusions on both occipital lobes.

Body wall/skeletal: Bruising of deep muscle layers of caudal sternum and right shoulder. Overlying soft tissue not affected.

Abdominal cavity: [abdominal fluid + kidney lesions]

*Cause of death:* Drowning/asphyxia

*Assessment of traumatic lesions:*

Cranium: Severe (based on occipital lobe contusions)

Subcutaneous/skeletal: Mild

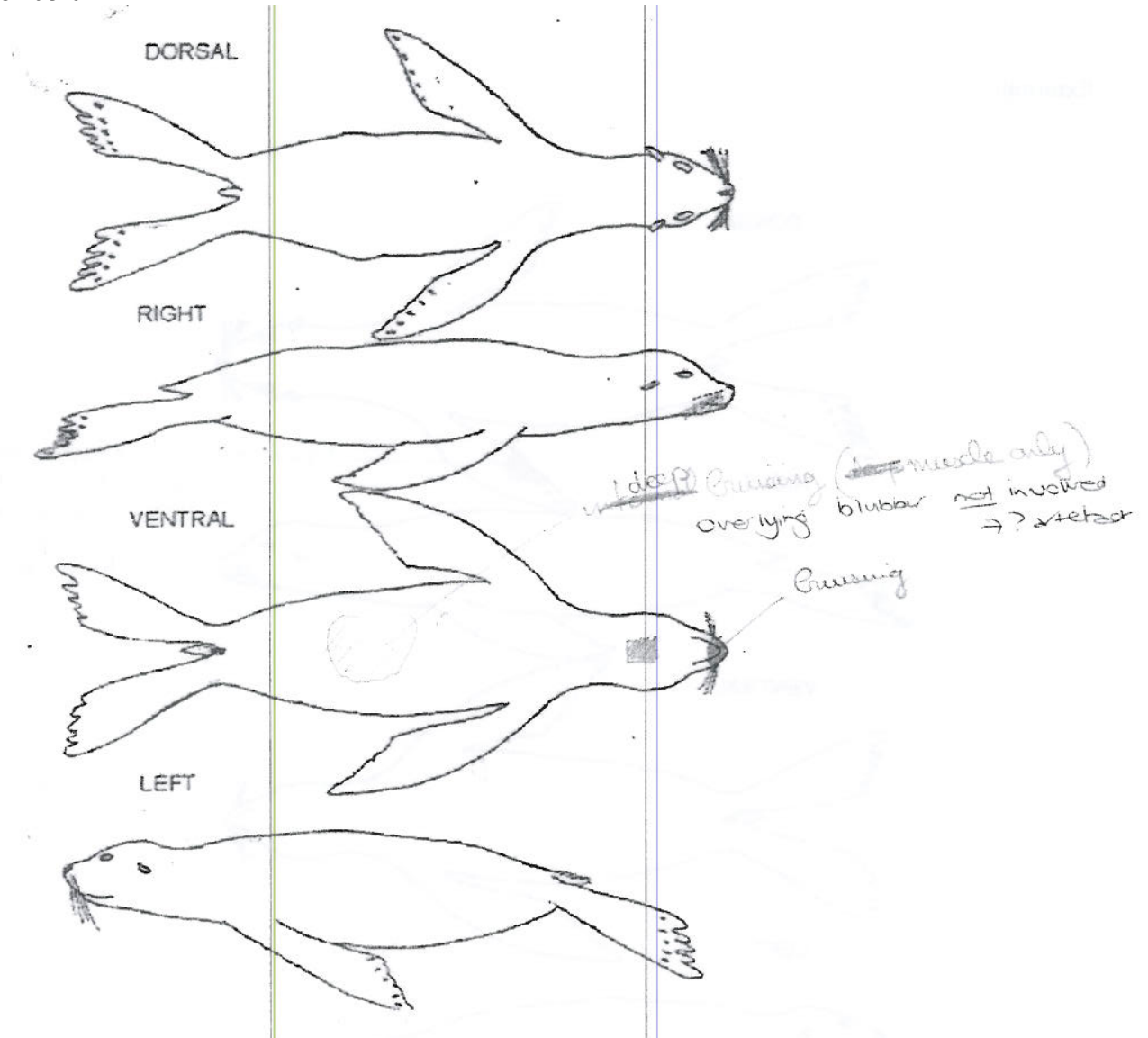
Body cavities: None

Overall assessment of trauma severity: **Severe**

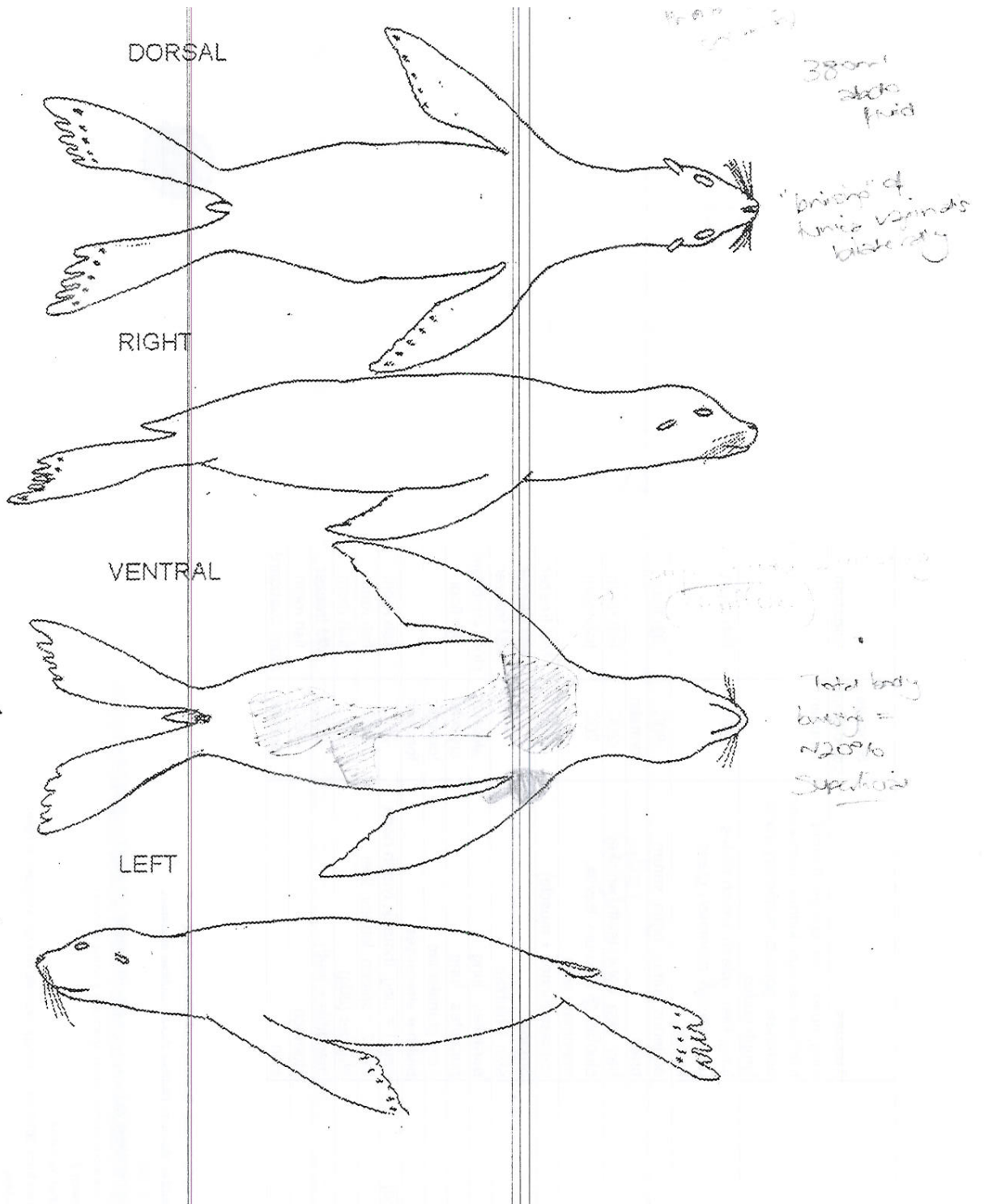
Appendix 2.

Diagrams depicting body wall trauma.

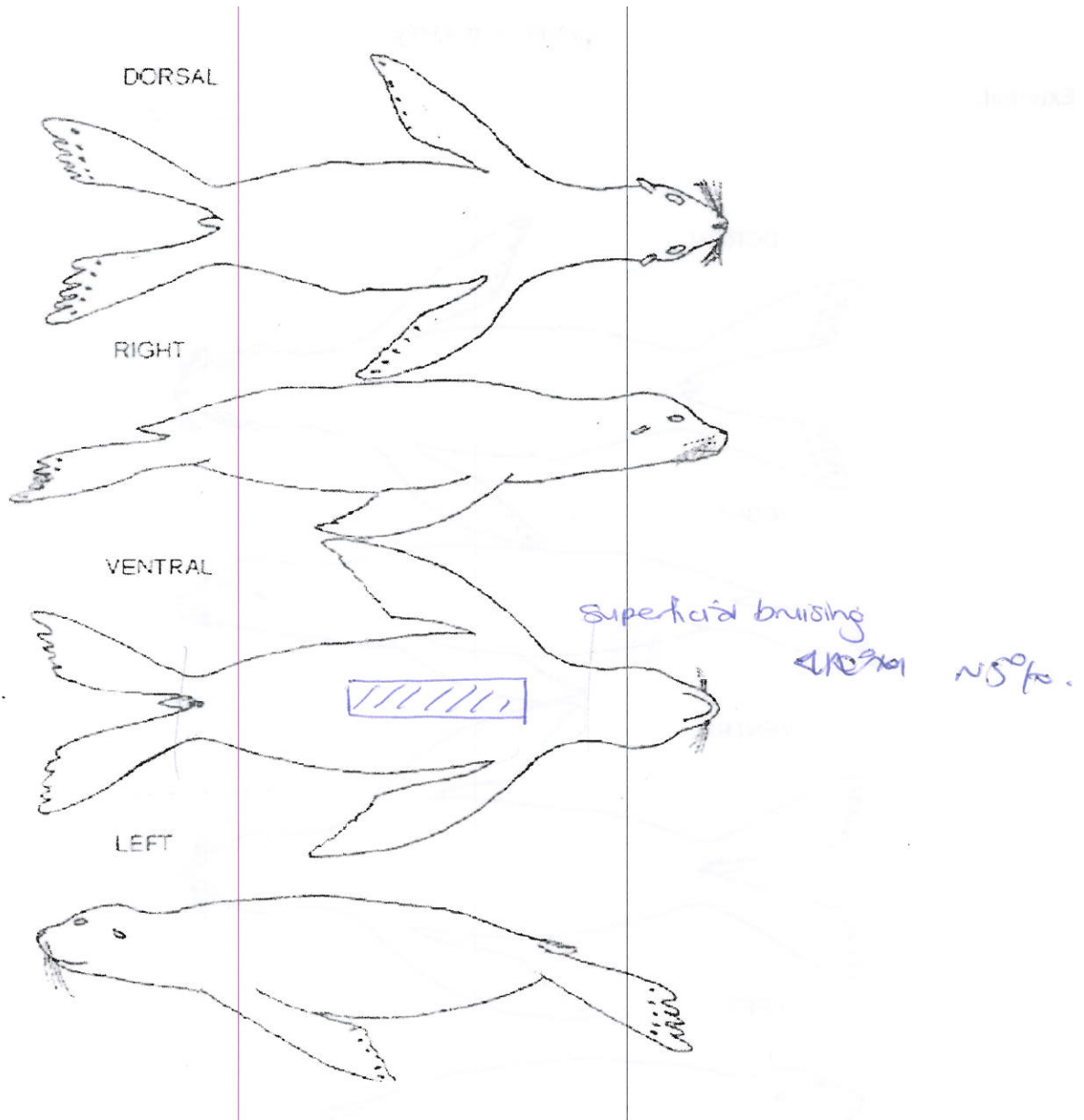
SB08-01Ph



SB08-02Ph

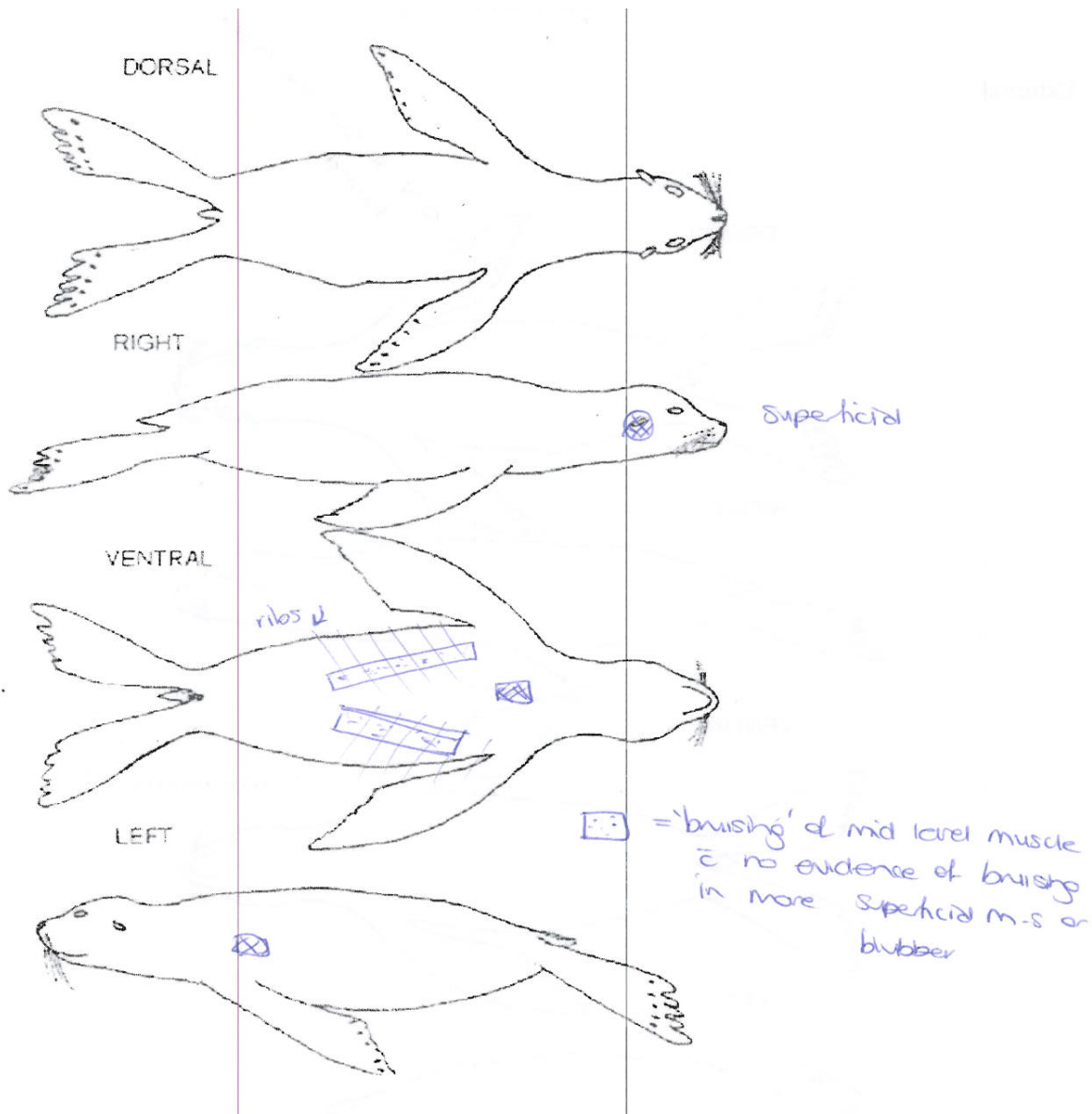


SB08-03Ph

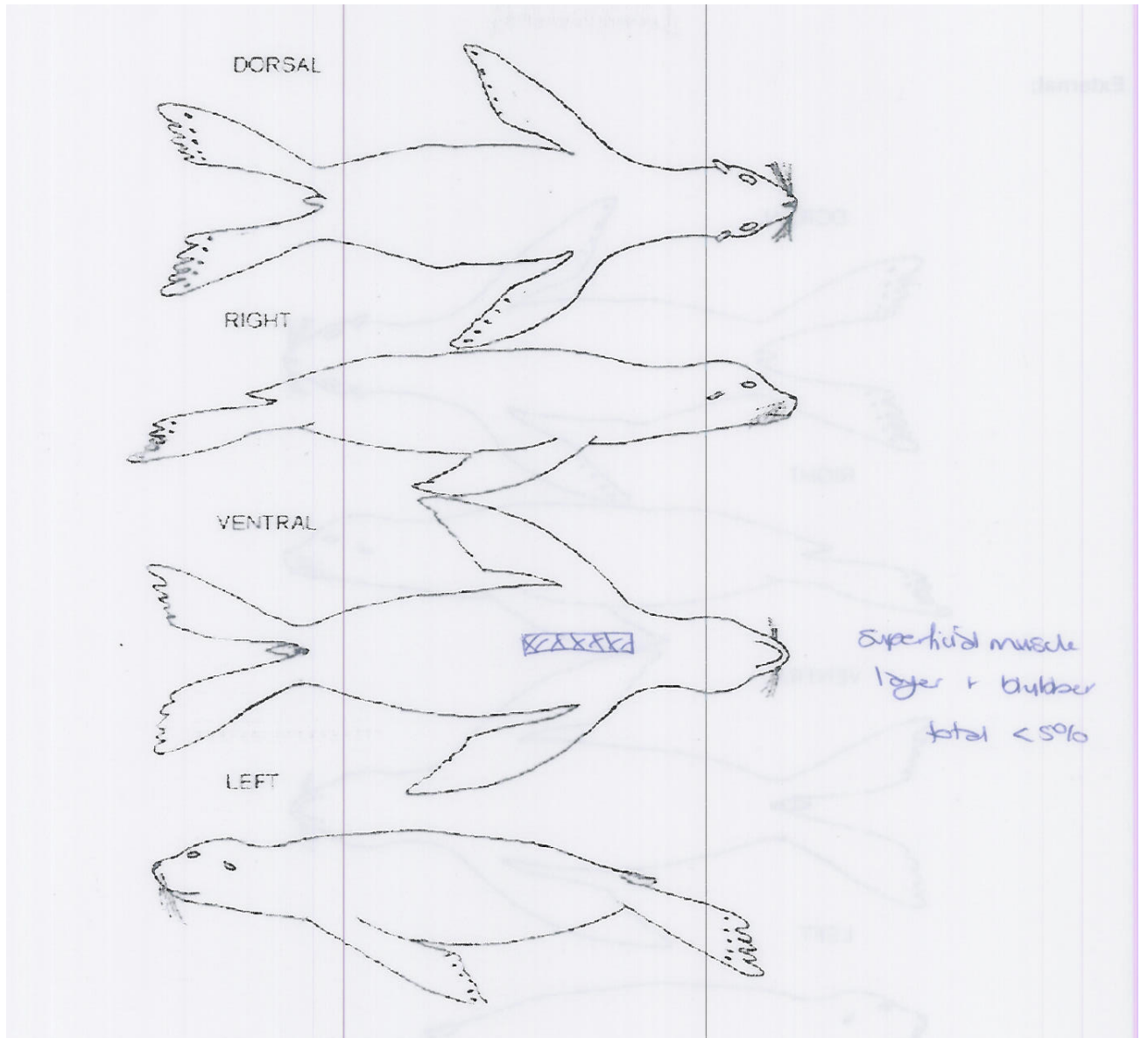




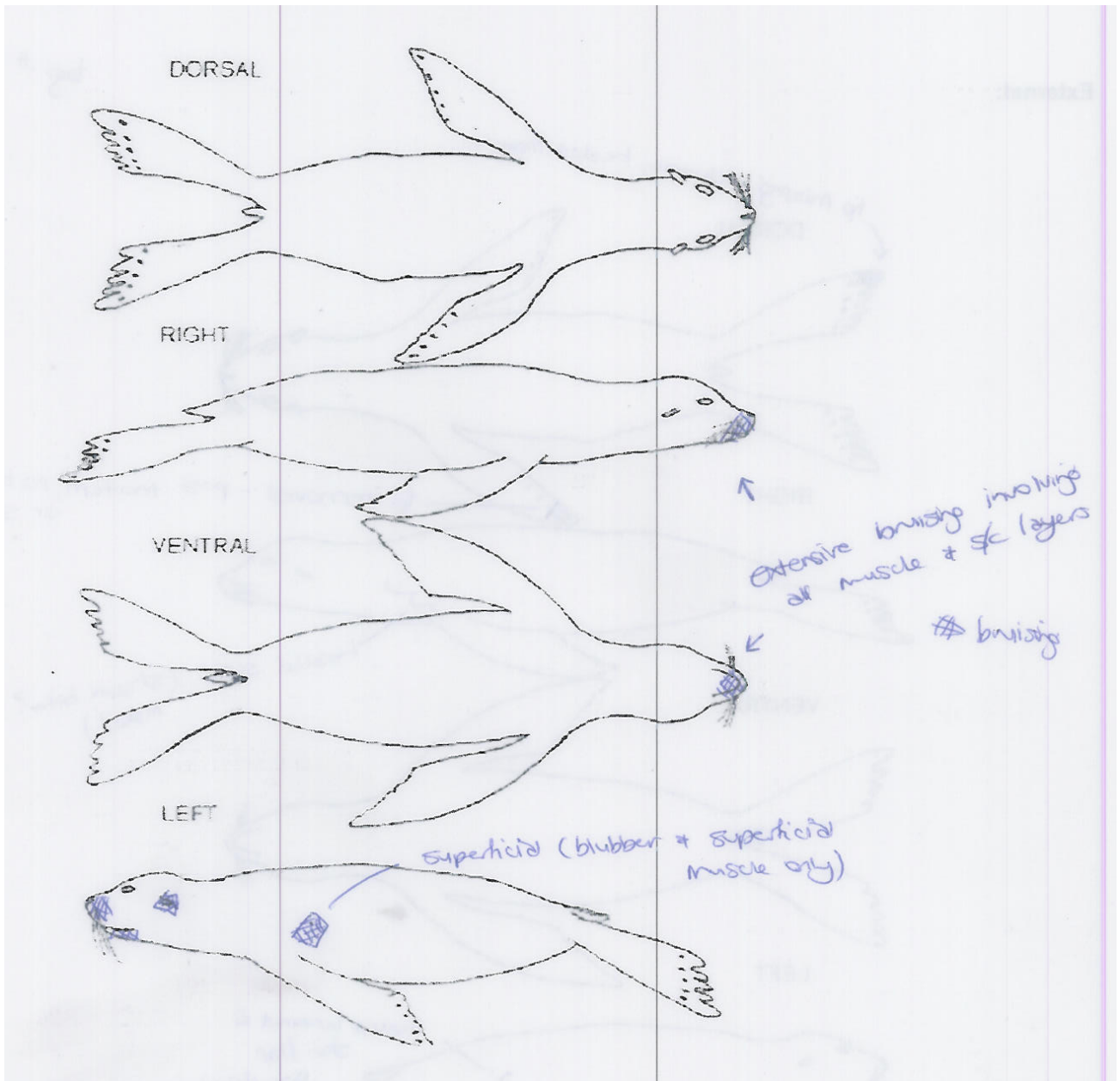
SB08-04Af



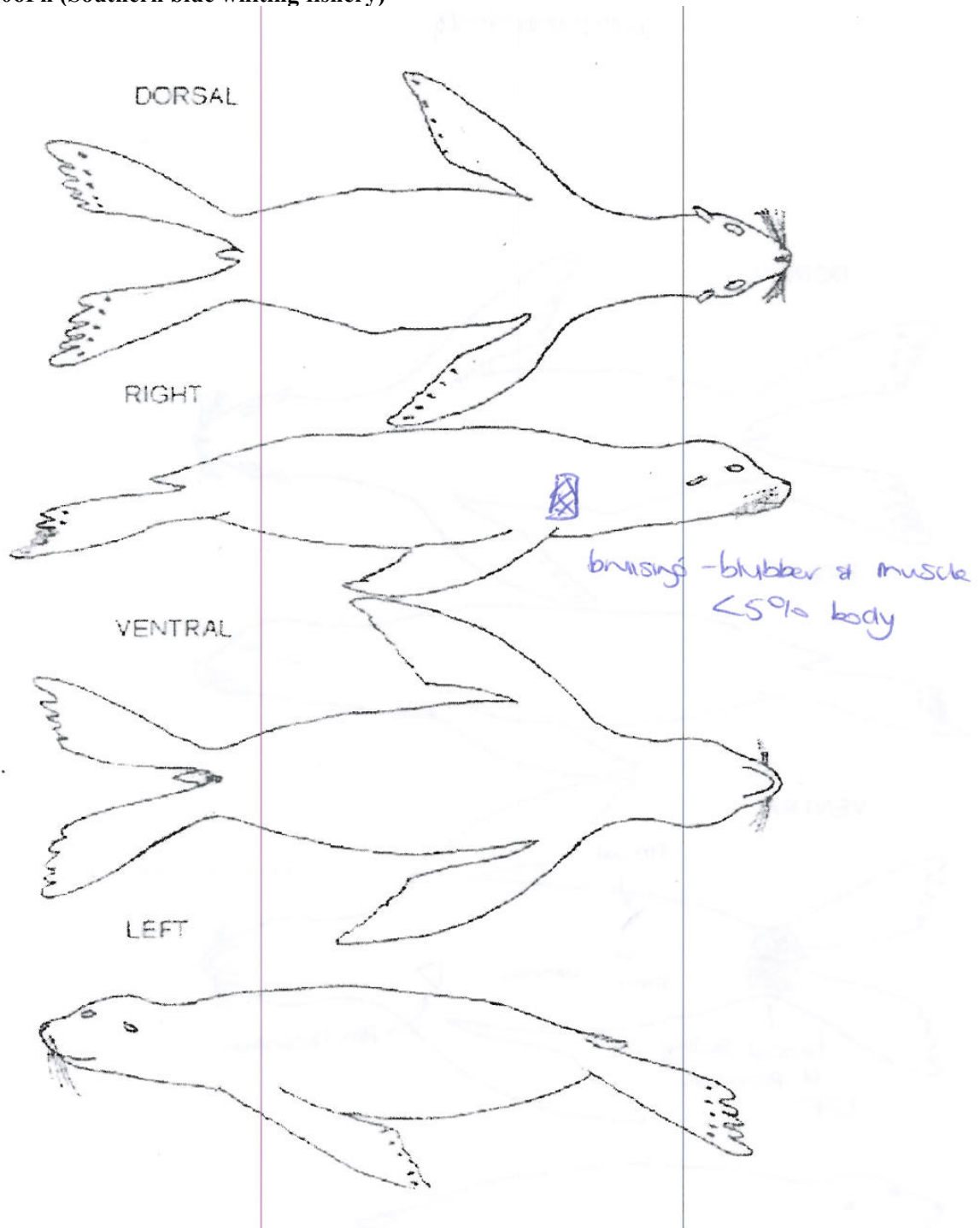
SB08-05Ph



SB08-09Ph



SB08-06Ph (Southern blue whiting fishery)



SB08-10Ph (Southern blue whiting fishery)

